

## **The Inframammary Semilunar Incision in Reduction Mammoplasty**

FOUAD M. GHAREEB, F.R.C.S.

*The Plastic Surgery Unit, Faculty of Medicine, Menoufiya University.*

### **ABSTRACT**

One of the most commonly seen complications in reduction mammoplasty is necrosis at the junction of the inframammary vertical and transverse incisions. In the majority of cases this heals spontaneously without leaving prominent deformity, but in some cases this progresses into massive necrosis leading to major skin loss. In these cases the resulting deformity and scarring is significant to undermine the result of this commonly performed procedure. The inframammary midline triangle was described in literature to overcome this problem. We have used this triangle for years and we have found out that we gain more satisfactory results by increasing its size. Then we have realized that by changing the inframammary incision into a semilunar incision has produced better results in our hands, not only as regard minimizing the necrosis at the junction due to decreased tension and increased number of subdermal vessels going to that portion, but also regarding the hiding of the inframammary incision on the back of the breast and minimizing the vertical infra-areolar incision. This procedure was applied in 35 consecutive cases of reduction mammoplasty and the results were analyzed to assess the credibility of this technique.

### **INTRODUCTION**

Reduction mammoplasty is one of the most commonly performed procedures in plastic surgery, a major disadvantage of which is the unsightly scar. This problem is more encountered by surgeons who are mostly dealing with oriental patients due to higher incidence of hypertrophic and hyperpigmented scars. In addition to that, necrosis at the junction of the vertical and transverse inframammary incisions may occur. A small triangle has been proposed to be left in the midline to decrease the tension on the junction of the vertical and transverse inframammary incisions [1,2,3]. Authors who adopted the procedure have compared the results between two groups where in the first they have used the midline triangle in conjunction with McKissock technique and in the second group they utilized McKissock or Robbins techniques without the

midline triangle and they have found out that no necrosis has occurred in the first group while in the second group 8 cases had necrosis or wound dehiscence at the junction of the vertical and transverse incisions [4]. The triangle, which has been described in the above mentioned group was small, as it had been shown in the photograph of the patient. Penn has described larger triangle aiming not to release tension but to improve the techniques, which was used at that time [5]. Methods have been described to minimize or eliminate the inframammary [6,7,8] or the vertical scars [9,10,11]. Younger patients are more liable to have hypertrophic scars because young breasts tend to be less pliable than older ones and the rigidity of the tissues of the flap bearing the nipple-areola complex sometimes renders the procedure hazardous [12]. Tension is the key word in occurrence of necrosis or hypertrophic scars in the mean time tension helps to make breasts firmer and more youthful. With increasing age there is inferior migration of the nipple and the vertical components of the breast except the medial end of the inframammary crease, producing lateral ptosis, these changes are due to the effect of gravity on the ageing breast with loss of dermal elasticity and glandular atrophy [13]. Also with increasing obesity, complications are more prone to happen in reduction mammoplasty [14].

We propose the inframammary semilunar incision to reduce necrosis at the junction of the vertical and transverse inframammary incisions, to minimize the vertical inframammary incision and to hide the inframammary scar at the back of the breast.

### **TECHNIQUE AND METHODS**

This technique was applied consecutively in

35 cases of McKissock (19 cases) and inferior pedicle (16 cases) reduction mammoplasties. The preoperative marking of the patient was done while the patient was in upright position. The marking was done as usual in both techniques by determining the position of the new areola and nipple complex to be 20 cm from the clavicular notch and nearly at the level of the inframammary crease utilizing the wise pattern. The selected radius of the areola was drawn to match that of the wise pattern. The superior pedicle was drawn if McKissock technique is chosen. The inferior pedicle was drawn with its base between 7 to 10 cm. The transverse inframammary line was planned as a semilunar line extending from aesthetically satisfactory positioned medial and lateral points with its top facing upwards and exactly at the midline and about 3 to 5 cm from the inframammary fold.

De-epithelialization was done around and below the areola to that line and it was noticed here that the effort of de-epithelialization was greatly reduced in this technique because only the upper part of the inferior pedicle is done (Fig. 1a and b). In this manner we do not de-epithelialize the lower part of the inferior pedicle which is difficult to do due to dermal gaps and tighter epidermo-dermal junction especially near the inframammary fold which increases the incidence of sloughing of the T-junction (Fig. 2a and 2b). The medial and lateral flaps were brought downwards to meet the semilunar inframammary incision after trimming of the corners of these flaps which are more vulnerable to necrosis. At this point the vertical incision was minimized and the transverse inframammary incision was replaced by the semilunar incision (Fig. 3a and 3b).

## RESULTS

Between December 1996 and March 2001 the author has done 35 cases of reduction mammoplasties utilizing McKissock (19 cases) and inferior pedicle (16 cases) techniques. In all these cases the author have used the semilunar incision. The age of the patients ranged between 21 years to 43 years. Between 430 grams to 2800 grams of breast tissues have been removed from each breast. No blood transfusion was given to any patient. Patients were discharged from hospital 1 to 3 days after surgery. The wounds healed primarily in all patients but one, which healed in 3 weeks with hypertrophic scar. All patients

were pleased with the results of the modification and in the preoperative consultation when they were given the choice between the usual inframammary incision and the semilunar incision with the help of postoperative pictures of previous patients, all of them preferred the semilunar incision (Fig. 4). The only complication, which was related to the technique, is broad breasts due to inadequate pull of the medial and lateral flaps during closure. This happened in one patient at the start of adopting the technique and could be avoided in later cases (Fig. 5). Technique non-related complications have occurred; like unilateral flat nipple (one case), hyperpigmented scars (4 cases), mild circumareolar scar stretch (2 cases), limited wound infection healed conservatively with mild hypertrophic scars (two cases).

We have found out that the dermis of the posterior surface of the breast has been thinned out and in some areas this progresses to the extent that gaps appear in this layer. The blood vessels were stretched and dilated and their walls are thinned out. The subcutaneous fat was also thinner than non ptotic breasts and instead of being condensed, it was separated to fat globules and had lost its tight contact with the deep surface of the dermis. These changes were not significant in the anterior surface of the breast. In our opinion these changes were marked in the posterior surface due to the fact that this surface is anchored to the chest wall at the inframammary line, so descent of the breast tissues expands the skin by stretching it, while in the anterior surface the descent of the breast tissues pulls the skin of the chest wall above the breast due to absence of this fixation.

## DISCUSSION

The main concern for plastic surgeons dealing with oriental patients is scars, how they can be avoided, concealed or dealt with. In reduction mammoplasty, the problem is more apparent and the patient has to choose between large unscarred breasts or normal sized breasts with the usual T-shaped scars. Hyperpigmentation and hypertrophy of scars occur in primary healed scars in oriental patients more than Caucasian patients and this could be worse if healing is delayed due to sloughing, fat necrosis or infection. The transverse inframammary incision, which looks very cosmetic in Caucasians, does not look so in many oriental patients especially if healing

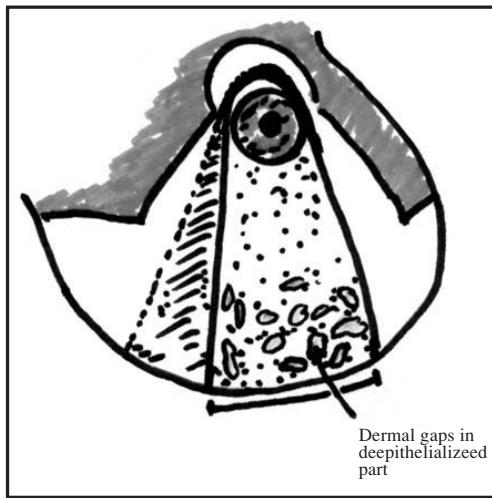


Fig. (1-A): Diagram of ordinary inferior pedicle after deepithelialization shows sites of dermal gaps exposing the subcutaneous fat.

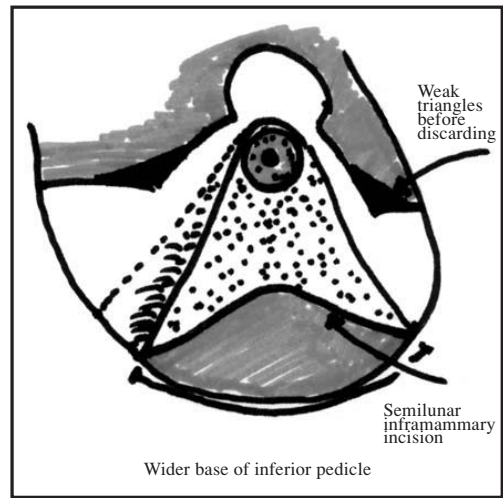


Fig. (1-B): Diagram shows the prescribed inframammary semilunar incision with wider base of inferior pedicle and weak triangles before discarding.

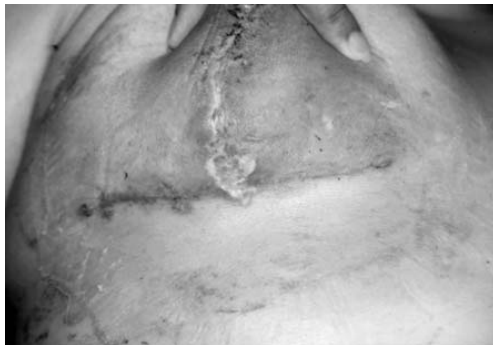

Fig. (2-A): Skin sloughing occurring at the T-junction after reduction mammoplasty.

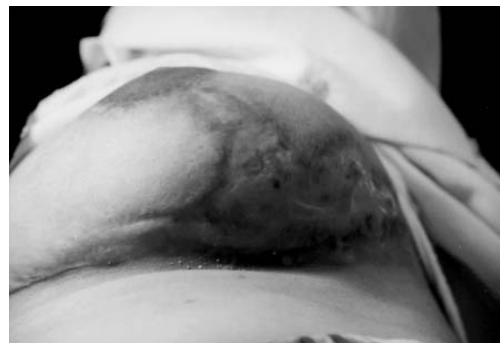

Fig. (2-B): Hypertrophic scar at the T-junction after healing of massive sloughing.

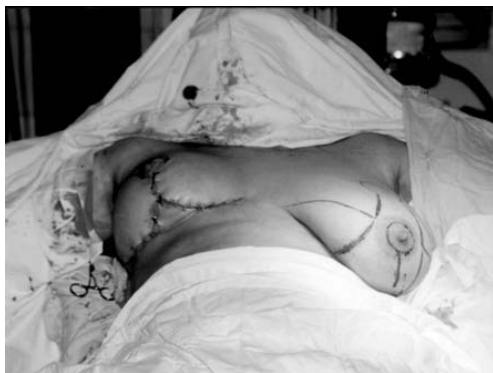

Fig. (3-A): The inframammary triangle as previously described.

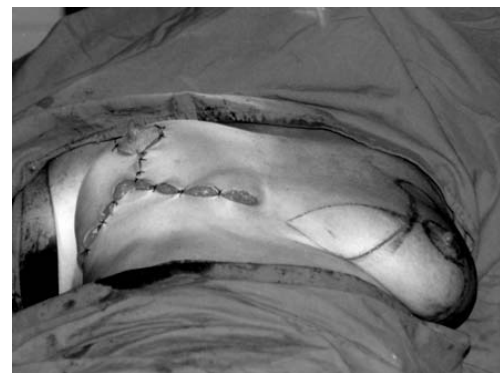

Fig. (3-B): The inframammary semilunar incision as a modification of the inframammary triangle.

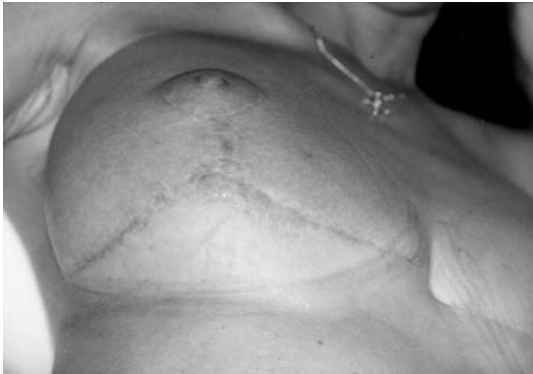

Fig. (4): Late postoperative photo of the same patient with inframammary semilunar incision.

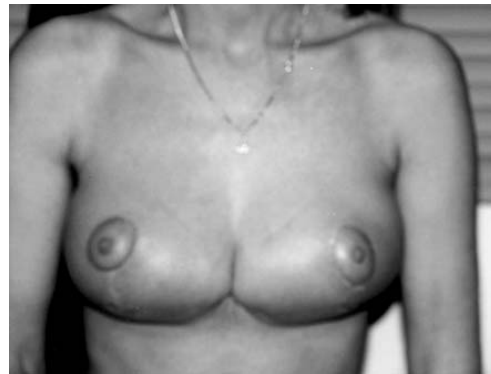

Fig. (5): Broad breasts due to inadequate approximation of the medial and lateral flaps.

is delayed at the T-junction of the vertical and transverse inframammary incisions. The inframammary triangle has been adopted successfully to overcome this problem [1-4]. Marchac and Sagher demonstrated that the skin of the breast has lesser tendency to form cicatrizing scars than that of the inframammary region [15]. We have observed during performance of huge reduction mammoplasties that the great stretch of the dermis and subcutaneous tissues has affected the structure of these tissues so that the subcutaneous fatty layer become less condensed and separated grossly into globules and in the mean time they become less adherent to the skin making the blood supply of these parts dependent mostly on the dermal blood supply and this may contribute to the necrosis of skin corners as in the T-junction. The dermis is also thinned out and even gaps are present in this layer, so that even during very careful deepithelialization, fat appears through these gaps and this in our opinion may contribute to interference of the blood supply to the areola and nipple and the skin corners. These findings more profound on the posterior surface of the breast due to the fact that this surface is anchored to the chest wall at the inframammary line, so descent of the breast tissues expands the skin by stretching it, while it pulls on the skin of the chest wall above the breast on its anterior surface due to absence of this fixation. The use of the semilunar inframammary incision has enabled us to discard these corners and have sound healing of scars. In the mean time we have partially concealed the inframammary incision at the back of the breast with better healing and less cicatrization. How-

ever, when necrosis is multiple and severe, we should suspect pyoderma gangrenosa which is an idiopathic necrotising cutaneous disorder associated with systemic diseases like inflammatory bowel disease, monoclonal gammopathy, arthritides and haematological malignancy. It occurs at sites of trauma, a phenomenon called pathergy [16]. Other objectives of this technique are minimization of the vertical inframammary scar, preservation of the dermal blood supply to the areola and nipple complex by elimination of deepithelialization near the inframammary fold which is found to be difficult and more hazardous in huge breasts due to the changes mentioned above.

## REFERENCES

- 1- May H.: Breast plasty in female. *Plast. Reconstr. Surg.*, 17: 351, 1956.
- 2- Hinderer U.T.: Dermal brassiere mammoplasty. *Clin. Plast. Surg.*, 3: 349, 1976.
- 3- Hoffman S.: The inframammary midline triangle in reduction mammoplasty. *Plast. Reconstr. Surg.*, 95: 1129, 1995.
- 4- Benmeir P., Lausthaus S., Neuman A., Weinberg A. and Wexler M.R.: The inframammary midline triangle in reduction mammoplasty: the renewal of an old idea. *Plast. Reconstr. Surg.*, 93: 413, 1994.
- 5- Penn J.: Breast reduction. *Br. J. Plast. Surg.*, 7: 357, 1955.
- 6- Regnault P.: Reduction mammoplasty by the B technique. *Plast. Reconstr. Surg.*, 53: 19, 1974.
- 7- Marconi F.: The dermal purse string suture: A new technique for a short inframammary scar in reduction mammoplasty and dermal mastopexy. *Ann. Plast. Surg.*, 22: 484, 1989.

- 8- De Longis E.: Mammoplasty with an L-shaped limited scar and retropectoral dermopexy. *Aesthetic Plast. Surg.*, 10: 171, 1986.
- 9- Ribeiro L.: A new technique for reduction mammoplasty. *Plast. Reconstr. Surg.*, 55: 330, 1986.
- 10- Han J.Q.: Reduction mammoplasty utilizing an inferior pedicle flap with no perpendicular scar. *J. Plast. Surg. Burns (Chung Hua Cheing, Hsing Shao, Shang Wai Ko, Tsa, Chih) (Chinese)*, 2: 330, 1986. Quoted from referene number 11.
- 11- Youssif N.J.: Larson D.L., Sanger J.R., Matloub H.S.: Elimination of the vertical scar in reduction mammoplasty. *Plast. Reconstr. Surg.*, 89: 459, 1992.
- 12- Maillard G.F.: AZ-mammoplasty with minimal scarring. *Plast Reconstr. Surg.*, 77: 66, 1986.
- 13- La H., Brown T.P., Ringrose C., Hyland R.E., Cole A.A. and Brotherston T.M.: A method of assessing female breast morphometry and its clinical applications. *Br. J. Plast. Surg.*, 52: 355, 1999.
- 14- Zubowski R., Zins J.E., Foray-Kaplon A., Yetman R.J., Lucas A.R., Papay F.A., Heil D. and Hutton D.: Relationship of obesity and specimen weight to complications in reduction mammoplasty. *Plast. Reconstr. Surg.*, 106: 998, 2000.
- 15- Marchac D. and Sagher U.: Mammoplasty with a short horizontal scar: evaluation of the results after 9 years. *Clin. Plast. Surg.*, 15: 627, 1988.
- 16- Gudi V.S., Julian C. and Bowers P.W.: Pyoderma gangrenosa complicating bilateral mammoplasty. *Br. J. Plast. Surg.*, 53: 440, 2000.